

68924-0

68924-0

FILED  
COURT OF APPEALS DIV I  
STATE OF WASHINGTON  
2013 MAR 12 PM 1:45

No. 68924-0

Court of Appeals  
Division I  
Washington State

---

LEONARDO C. MARIANO, *pro se*  
Plaintiff/Appellant

v.

SWEDISH CARDIAC SURGERY  
Defendant/Appellee

---

---

**APPELLANT'S REPLY**  
to  
**RESPONDENT'S BRIEF**

---

---

Leonardo C. Mariano, *pro se*

1123 Rainier Av. # 415  
Everett, WA 98201  
(425) 317-0854  
[mariano.leonardo@ymail.com](mailto:mariano.leonardo@ymail.com)

March 11, 2013

R E F E R E N C E S

Page

SELECTED CLERK'S PAPERS (CP page and Reply page)

<u>(CP - 32)</u> p. 13:	<u>(102)</u> p. 6:	<u>(103)</u> p. 6:	<u>(106)</u> p. 7:
<u>(108)</u> p. 6, 9:	<u>(110)</u> p. 9:	<u>(113)</u> p. 5, 8:	<u>(115)</u> p. 2, 4, 8
<u>(116)</u> p. 2, 4, 6:	<u>(121)</u> p. 14, 14:	<u>(124)</u> p. 2, 7, 7, 8, 10, 12:	
<u>(128)</u> p. 11:	<u>(129)</u> p. 13:	<u>(132)</u> p. 8, 9, 9, 12:	
<u>(133)</u> p. 10:	<u>(134)</u> p. 7, 9, 13:	<u>(135)</u> p. 5:	
<u>(136)</u> p. 13:	<u>(137)</u> p. 9:		

COURT DECISIONS

<u>Bell v. State</u> , 147Wn2d 166, 181, 52 P.3d 502 (2002). . . . .	3
<u>Douglas v. Freeman</u> , 117 Wn2d 242, 250, 814 P.2d 1160 (1991). . . . .	3
<u>McLaughin v. Cooke</u> , 112 Wn.2d 829, 838, 774, P.2d 1171 (1989). . . . .	3
<u>Pacheco v. Ames</u> , 149 Wn.2d 431, 436, 69.P.39,324 (2003). . . . .	2
<u>Shellenbarger v. Brigman</u> , 101 Wn.App.339, 347, 3 P.3 211(2000).	3

LAWS AND RULE

1. <u>RCW 4.24.290</u> . . . . .	8
2. <u>RCW 5.45.020</u> . . . . .	3
3. <u>RCW 7.70.030; 040; 050(1); 060</u> . . . . .	5, 8, 10

EXHIBITS

A. Mayo Clinic on Reliance of Cardiac Catherterization. . . . .	5
B. Mayo Clinic on Appropriateness of Heart Bypass. . . . .	7, 9, 13
C. Johns Hopkins on Heart Bypass versus Angioplasty/Stent. . . . .	9
D. Cleveland Clinic on Current Acceptance of Angioplasty/Stent. . . . .	9
E. Interrogation of Swedish on Wrong Diagnosis . . . . .	4
F. Email of Swedish of Importance of Medical Consultant/Witness:	
1. Dated October 12, 2011. . . . .	3
2. Dated November 28, 20 . . . . .	3
G. Transesophageal Report . . . . .	11, 11

## MAIN ISSUE

In its Brief, Swedish has requested the Court of Appeals to “*affirm the Trial Court’s decision dismissing Mr. Mariano’s claims in their entirety because Mr. Mariano failed to come forward with admissible evidence sufficient to meet his burden on this medical negligence claim”.* (Page 13 of Brief)

In contrast, Appellant maintains that the Trial Court erred by ignoring the documentary evidence submitted by Appellant and by concentrating on testimonial (given orally) evidence.

In Webster’s College Dictionary, 1991 Edition, page 463, the word evidence is defined as:

“ .... 3. *Data presented to a court or jury to substantiate claims or allegations, including testimony, records or objects ....*”

Appellant submitted three, among many, documentary evidence which were the results of diagnostic cardiac catheterization and coronary artery bypass done by Swedish. These evidence substantiate Appellant’s claims of wrong diagnosis and unnecessary bypass.

Both parties differ in their definition of evidence. The Trial Court and Swedish focused on “expert witness”, “expert testimony”, “expert opinion, “medical consultants” and the like. Appellant relied more on available quality documents, not by choice but because paid medical witnesses and consultants are not affordable.

LEGAL FOUNDATIONS OF APPELLANT'S EVIDENCE

Appellant's claims of wrong diagnosis and unnecessary bypass are supported by three major reports: a) cardiac catheterization/coronary arteriogram (diagnosis) by Dr. John Petersen (CP p. 124), b) coronary artery bypass graft by Dr. David Gartman (CP p. 116) and c) letter summarizing the diagnosis by Dr. Petersen (CP p. 115). These three documents have two things in common.

- a). All are owned by Swedish itself, which is under estoppel from issuing any challenge or objection for their admissibility in court.
- b). All speaks for themselves in a straight-forward manner, with no room for different interpretations.

*"..... The res ipsa loquitor doctrine allows the jury to infer negligence where three elements are met: (1) the accident or occurrence producing the injury is of a kind which ordinarily does not occur absent someone's negligence; (2) the injuries were caused by an agency or instrumentality within the control of the dependant; and (3) the injury-causing accident or occurrence was not due to any voluntary action or contribution on the part of the Plaintiff."*  
Pacheco v. Ames, 149 Wn.2d 431, 436, 69.P.39, 324 (2003).

Since all elements are met, the doctrine of *res ipsa loquitor* is applicable to the three evidence. On the 2<sup>nd</sup> and 3<sup>rd</sup> elements, the injury was caused solely by Swedish while Plaintiff had no part at all. On the 1<sup>st</sup> element, the issue is not HOW but WHY regarding the diagnosis and bypass. Even with negligence, it is not usual for a diagnosis to be way off the mark and for an operation to be done on an artery which is not a candidate for a bypass. These events do not ordinarily occur and they were reported by Swedish Dr. Petersen and Dr. Gartman themselves

The above three evidence are supported by existing laws and court opinions.

*“The Plaintiff may obtain from the Dependant, testifying as an adverse witness, the required expert testimony”* Douglas v. Freeman, 117 Wn.2d 242, 250, 814 P.2d 1160 (1991).

*“Medical records are generally relevant and admissible in a medical malpractice trial.”* Bell v. State, 147Wn2d 166, 181, 52 P.3d 502 (2002).

*“Reports of lab test results contained in the physician’s medical file are admissible ....”* RCW 5.45.020.

Swedish wrongly argued that the testimony of an expert witness is a must requirement in any medical malpractice case:

*“... Court Rule (CR 11), together with the statutory requirements under RCW 7.70, compel you to have supporting testimony from a qualified medical expert witness PRIOR to filing a medical malpractice lawsuit.”*  
Defendant’s Email to Plaintiff dated October 12, 2011 (Exhibit F-1).

After examining said CR 11 and RCW 7.70, also Rules 26 to 37. on deposition and discovery and parallel LCR’s, Plaintiff found no such injunctions.

Swedish has given outmost importance to the role of expert witness, it was willing to sacrifice its summary judgment vehicle for it:

*“ ... if you provide me with the name of an expert witness supporting your claim at any time before the hearing, I will likely strike the hearing (on the summary judgment motion).”* Defendant’s Email to Plaintiff dated November 28, 2011 (Exhibit F-2).

However, an expert witness is overrated as decided in two cases below:

*“(Expert testimony) .... is not required when medical facts are observable by a layman’s senses and describable without medical training.”* McLaughlin v. Cooke, 112 Wn.2d 829, 838, 774 P.2d 1171 (1989).

*“A malpractice case may be proved without the aid of expert testimony by a chain of circumstances from which an ordinary layman may reasonably and naturally infer the ultimate fact required to be established”.* Shellenbarger v. Brigman, 101 Wn. App. 339, 347, 3 P.3 211 (2000)

### WRONG DIAGNOSIS

Swedish identified the right artery as the source of Plaintiff's discomfort and which needed a bypass. However, the diagnosed right artery was later found out fully calcified and harmless and its functions already taken over by corollary arteries

In his summary letter on the diagnosis (cardiac catheterization), Dr. John Petersen stated:

*" ... now that I know the anatomy with the critical lesion in his right coronary artery that I suspect is the culprit lesion ..... the best approach in this case is with direct coronary revascularization (bypass) ... "* (CP p. 115).

However, no surgery was done on the diagnosed right artery since there was nothing to operate on. Dr. David Gartman, after opening Plaintiff's chest, reported that:

*" ... right coronary artery were so hard throughout their length, there was nothing I could do with those .... "* (CP p. 116).

1. Admission. In its attempt to justify its action, Swedish inadvertently admitted the error with these words in Defendant's Answers to Plaintiff's First Set of Interrogatories, October 4, 2011, p.2:

*" .... coronary right artery were so damaged that they could not be salvaged or used in connection with the bypass procedure to establish coronary revascularization. "* (Exhibit E).

The quotation is also incriminating for Swedish if the intention was to use part of the right artery to serve as a graft vessel for the bypass in the unplanned left artery. That would have been unusual. The primary sources for any graft are the saphenous vein from the leg and the internal mammary artery from the inner wall of the chest. As diagnosed, the right artery was targeted for surgery because it was diseased. It was not meant to supply a graft for the bypass in the left artery.

2. Reliance. Swedish used coronary angiography as a diagnostic tool which, however, was not reliable in determining the cause of Plaintiff's heart problems:

*" ... While angiography is an accurate test that provides extensive information, it doesn't always provide the specific information your physician is looking for. For example abnormalities in the coronary arteries may be found in the coronary angiogram, but these abnormalities may not be the cause of your chest pain..." (CP - 135 and Exhibit A).*

3. Multiple Treatments. Swedish did not consider whether Plaintiff's other medical ailments had contributed to his heart problems. The wake-up symptom for an impending heart attack was intense pain which radiates to other parts of the body which Plaintiff did not experience.(CP p.113) . Rather his symptoms were basically shortness of breath and chest discomfort. Thus, Plaintiff was referred to other doctors in Everett Clinic where Appellant is a patient. Dr. George Cox on acid reflux and hiatal hernia, Dr. Michael Tamber on thyroid nodules, Dr. Ronald Green on lung lesions, Dr. Michael Millie on gallstone , Dr. Frank Sheridan on the heart and Dr. John Lank on diabetes and blood pressure. Dr. Neale Smith, cardiologist at Western Washington Medical Group, was also consulted.

4. Contemporary Findings. Swedish ignored other studies by several veteran cardiologists which revealed that Plaintiff's right artery was relatively healthy, contradicting the dire assessment of Swedish. Meaning, there was free flow of blood in the arteries of the heart. Thus, Swedish violated a major provision of RCW

7.70.040:

*" .... exercise that degree of care, skill, and learning expected of a reasonably prudent health care at that time in the profession or class to which he belongs, in the State of Washington, acting in the same or similar circumstances."*

a). In the Nuclear Scan Myocard Spect Rest/Stress done on August 11, 2005 (eight months before the bypass), Dr. Neale Smith of Western Washington Medical Group reported:

*“ .... no ischemia is identified. .... nuclear medicine portion showed normal left ventricular systolic function.... ” (CP p. 108) .*

b). In the Stress Test done January 20, 2003, Dr. Frank Sheridan of the Everett Clinic reported:

*“ .... patient was able to exercise for 9 minutes without any chest pain.... this test is interpreted as negative for ischemia ” (CP p. 103).*

c). In the echocardiogram test done January 19, 2000, Dr. Kirk Prindle of the Everett Clinic reported:

*“ .... No evidence of reversible coronary artery blood flow abnormalities ..... He falls into the lowest possible risk group.... the likelihood of having a normal life expectancy is superb ” (CP p. 102).*

### UNNECESSARY BYPASS.

Dr. David Gartman, Swedish's surgeon, performed an unplanned heart bypass in the LEFT artery:

*“ ... Coronary artery bypass graft x 4 with IMA (LEFT internal mammary artery to LAD (LEFT anterior descending ..... to LEFT ventricular extension branch ” (CP p. 116).*

However, in direct contrast to Dr. John Petersen's diagnosis, the left artery was relatively healthy and not requiring surgery, unlike the right artery which was found to be harmless.



*“LEFT main: Moderate calcification ..... but no critical stenosis.”*

*.....  
“RIGHT coronary artery: Heavily calcified ..... and an 85 to 90 % stenosis” (CP, p. 124).*

-

1. Appropriateness. According to Mayo Clinic, coronary bypass surgery is an option if:

- \* *“You have severe chest pain caused by narrowing of several of the arteries ....*
- \* *You have more than one diseased coronary artery and the heart’s main pump - the left ventricle - is not functioning well.*
- \* *Your left main coronary artery is severely narrowed or blocked. This artery supplies most of the blood to the left ventricle” (CP - p. 134 and Exhibit B).*

The unplanned bypass on the left artery done by Swedish was unnecessary because none of the above conditions were met. Specifically,

Re main left artery above. In the coronary angiography, Dr. John Petersen stated that this artery had only *“moderate calcification in its lumen but no critical stenosis”* (CP p. 124).

Re left ventricle above. In the echocardiogram , Dr. Neale Smith of the Western Washington Medical Group stated: *“... The left ventricle is normal in size....There are no wall motion abnormalities”* (CP p. 106).

Re chest pain above. Plaintiff had no severe chest pain, only shortness of breath. In his evaluation report dated March 21, 2006, Dr. John Petersen stated: *“... It has not*

*been a radiating pain. It does not go to the jaw or down the arms” (CP p. 113).*

Repeat, none of the three conditions above were met.

2. Consent. Two Washington State laws expressly prescribe that medical procedures, such as bypass surgery, angioplasty, among others, cannot proceed without the informed consent of the patient:

*“... in no event shall the provisions of this section apply to an action based on the failure to obtain the informed consent of a patient” RCW 4.24.290.*

Medical liability can be established if “... *the injury resulted from health care to which the patient or his representative did not consent*” RCW 7.70.030.

Plaintiff signed the consent form for a bypass which is handwritten in the blank spaces as follows:

*“Blocked heart blood vessels. (coronary artery disease).....coronary artery bypass graft)” (CP p. 132).*

The above words are not a blanket mandate for Swedish to operate in **ALL** arteries of the heart. As stressed earlier, the diagnostic test identified only the right artery needing treatment (CP p. 115). The left artery could not be included because it was relatively normal (CP p. 124) and, as explained earlier, the left artery did not meet all the conditions for a bypass surgery.

Printed in the consent form, not in a blank space, two pieces of advice are directed

to Plaintiff before signing:

*“Washington State law guarantees that you both have the right and obligation and obligation to make decisions concerning your health care. Your physician can provide you with the necessary information and advice, but as a member of the health care team, you must enter into the decision making process”* (CP p. 132).

*“I (Plaintiff) have the right to decide whether to accept or refuse medical care. I will ask for any information I want to have about my medical care and will make my wishes known .....”* (CP p. 132, back side of form.).

A brief background will explain such wishes. Swedish was approached for a second opinion due to two contrasting findings. Dr. Neale Smith reported the absence of ischemia (CP p. 108) while Dr. Frank Sheridan recommended angioplasty/stent for the damaged right artery (CP p. 110). Plaintiff made known in no uncertain term to Dr. Petersen to exclude as a treatment option the highly invasive bypass surgery due to a higher risk from old age (76 years old at that time). Worst scenario in case treatment was required, the less invasive angioplasty (PTCA) or stent was preferred.

There has been a running debate on which is the better procedure - bypass or stent. The Everett Clinic (where Plaintiff is a patient) has long been an advocate of the latter (CP p. 137). As pointed out by Mayo Clinic (CP p. 134 and Exhibit B), the extremely invasive bypass operation is appropriate only in cases of severe and multiple blood blockages. The No. 1 ranked heart hospital in the United States, John Hopkins, has listed several advantages of stent over bypass (Exhibit C). Another reputable source, Cleveland Clinic, reported the current trend of performing more less -invasive surgeries, such as angioplasty/stent (Exhibit D).

In the consent form to perform diagnosis, the treatment procedure was handwritten in the following words:

*“Coronary Arteriogram...Possible Angioplasty/Stent” (CP p. 133).*

For reasons detailed in two topics below, Plaintiff’s wishes were not carried out.

3. Suppression of Evidence. Defendant failed to comply with the provision of RCW 7.70.050 (1) cited in full below because of its importance in establishing informed consent:

*“ (1) The following shall be the necessary elements of proof that injury resulted from health care in a civil negligence case of arbitration involving the issue of the alleged breach of the duty to secure an informed consent by a patient or his representative against a health care provider:*

- (a) That the health care provider failed to inform the patient of a material fact or facts related to the treatment;*
- (b) That the patient consented to the treatment without being aware of or fully informed of such material fact or facts;*
- (c) That a reasonably prudent patient under similar circumstances would not have consented to the treatment if informed of such material fact or facts;*
- (d) That the treatment in question proximately caused injury to the patient.”*

The fact suppressed was the final report on the diagnostic cardiac catheterization done by Dr. John Petersen on March 30, 2006 (CP p. 124) . After numerous demands for its release, this report was received only on April 27, 2011 or five years later, precisely

because of its incriminating content. As revealed in this report, the left main artery had only “*moderate calcification in its lumen but no critical stenosis.*” In sharp contrast, the right main artery was found to be “*heavily calcified throughout its coursing and an 85 to 90 % stenosis.*” Meaning, there was a good reason to target the right artery for a bypass but no reason at all to subject the left artery to an unnecessary surgery.

Appellant discovered another suppressed report a week ago while finalizing this Reply. Five years after the surgery, Swedish’s lawyer released a disc of Appellant’s medical records: “*These records are a copy of your complete chart as maintained by Swedish.*” (CP p. 128) Because it consists of 285 pages of unorganized medical reports repeated several times and minor administrative details, Appellant initially set it aside. With more time on hand now, this two-page Transesophageal Report was extracted from the 285-page disc and being submitted (Exhibit G).

The new suppressed item is titled Perioperative Transesophageal which dealt with the ventricular function and valvular assessment of the heart. Clearly, it is incriminating for Swedish because all parts of the heart were found practically NORMAL. They are the right and left atria; right and left ventricles; tricuspid, pulmonic, mitral and aortic valves; pericardium , and interatrial and interventricular septums. Also, there was NO atherosclerosis in the ascending aorta and only mild atherosclerosis in the descending aorta. (Exhibit G )

Repeat. The above suppressed facts (two final medical reports) were not available when the two parties were discussing the requirements of the consent forms.

With these two documentary evidence, including the arguments in item 1 (appropriateness) just above, Swedish could not justify operating on the left artery which was relatively healthy.

4. Under Duress. Plaintiff signed the consent form under duress on March 30, 2006 , while still groggy from his diagnostic cardiac catheterization, under general anaesthesia The diagnosis started on 12:24 pm and ended a few hours later (CP p. 124) . At the 3:45 pm of the same afternoon, Plaintiff was asked to sign the form (CP p. 132).

**RES IPSA LOQUITUR.**

---

---

**OTHER ISSUES**

This Reply is focused on evidence which, according to Swedish, is the only major issue. (Page 1 of Respondent's Brief.)

For the following secondary issues, please refer to pages 11 to 16 of Appellant's Reply to Respondent's Brief:

1. Summary Judgment
2. Statute of Limitation
3. Full and Fair Hearing Denied.

## DAMAGES

This issue of damages is given special treatment as a strong reaction to the contention of Swedish that “ .. *Plaintiff Has No Damages Related to Alleged Negligence*”, asserting a) “... *he has no demonstrable damages.*” and that he admits that b) “ ...the bypass operation was a success.” CP- p. 32. Meaning (according to Swedish) since the bypass was a success, therefore, Appellant cannot seek damages.

On Swedish allegation of no demonstrable damage (item a) above): The effects of the heart bypass on Plaintiff are graphically described in other documents which are not repeated here for brevity. After the operation, Appellant is now a health wreck and is not even half of his normal self. Walking is off-balance, meals are an ordeal due to loss of appetite, past shortness of breath has not improved, words heard are not processed well, requiring the use of captions while watching TV, became unemployable and left with zero social life.

(For more, please refer to Complaint (CP - 56), page 19 of Appellant’s Brief and page 17 of Appellant’s Response to Respondent’s Motion to Affirm.)

Bypass is extremely invasive as described by medical clinics (CP - p. 129 to 131, 134, to 136; also Exhibit B). The chest was opened wide and the sternum realigned. **Worst, the chest was opened a second time several hours after the main operation due to complications.** While the newly-harvested clean artery/vein grafts were being attached to the diseased artery, the flow of blood continued with the installation of a mechanical heart. Expected interruptions in the blood flow during this stage of the operation, even by few seconds, impacted on every organs of the body. The

damage was overly massive that Appellant, after the bypass, has to learn how to walk, how to breath and even how to restart routine toilet activities.

On Swedish's allegation that Appellant cannot seek damages (item b) above). In a letter dated October 20, 2009 (CP -121-), Appellant stated " .... *the bypass operation was a success*" (first paragraph). Swedish has taken that statement out of context.

In the Complaint dated May 2, 2011, Appellant stated "*the letter (CP - 121 ) was written in non-confrontational tone to encourage Defendant to respond.*" This was not given under oath. In this same letter, Appellant asked a direct question: The right artery was diagnosed needing a bypass but why was the left artery the one operated?

After waiting for about 2 years, Swedish still did not respond. Appellant then decided to file the complaint in court to compel Swedish to answer. In this complaint and in succeeding documents, Appellant declared under oath that the bypass was not a success.

CONCLUSION

Appellant respectfully requests the Court of Appeals to reverse the grant of Respondent's Motion of Summary Judgment by the Superior Court and -- -- either a) to remand the case to the Superior Court for a full regular trial before a jury - -- or b) for the Court of Appeals to decide Appellant's claims of wrong diagnosis and unnecessary bypass on merits.

  
LEONARDO C. MARIANO, *pro se*



# MAYO<sup>A</sup> CLINIC

---

# HEART BOOK

---



## Why not use angiography first to diagnose heart disease?

Angiography, which allows your doctor to see blood vessels, would seem to be the final word for diagnosing problems in your coronary arteries or the blood vessels. So why isn't it the first-line test used to diagnose all heart disease? And why do questions remain even after angiography is performed?

Some of the answers to these questions have already been discussed. Angiography is expensive, it requires special equipment and specially trained medical staff, and it carries some risk with it, though this risk is relatively small. There are other reasons, however. While angiography is an accurate test that provides extensive information, it doesn't always provide the specific information your physician is looking for. For example, abnormalities of the coronary arteries may be found on the coronary angiogram, but these abnormalities may not be the cause of your chest pain.

What the coronary angiogram does best is provide a road map to your blood vessels. Simply looking at a road map of a city doesn't necessarily tell you what the traffic patterns in the area are. To find out where the bulk of the traffic is, perhaps a satellite view of car exhaust gases would be useful. Similarly, to find out what the "traffic patterns" actually are for your heart's oxygen and blood supply, a thallium scan may provide more valuable information. In most cases, more than one test is needed to provide complementary information that puts the whole picture of your condition into focus.

Of course, it isn't really the coronary artery that is being seen, but the image of the contrast material in the hollow part (lumen) of your artery. If there are partial or total blockages of the coronary arteries by atherosclerotic plaque or blood clots, these show up as irregularities or places where the image of the contrast material cuts off.

### Left ventriculography

At the same time you undergo coronary angiography, you may often have a contrast agent injected into your left ventricle. This procedure, called left ventriculography, shows how well your left ventricle is pumping. This also reveals its shape and internal structures and whether there is any back leakage (regurgitation) through the mitral valve. If leakage is present, the contrast material can be seen flowing backward into the left atrium.

### Angiography in peripheral blood vessels

Angiographic techniques can be used to see blood vessels in other parts of your body—even those in your brain. It also can be used in the blood vessels to your legs or arms (performed there, it's called arteriography), the aorta and its main branches (aortography), and selected blood vessels to specific organs. Angiography in your brain is performed by neuroradiologists. Specialists called vascular radiologists perform angiography in many other areas.

### Cardiac catheterization for congenital defects

Other uses of cardiac catheterization include examining congenital malformations of the heart. It can be used to assess the degree of shunting of the blood through a septal defect (a hole in your heart) or through abnormal connections of the arteries (see page 66). It does this by measuring the oxygen in the blood in your heart.

B



## Coronary bypass surgery

By Mayo Clinic staff

---

**Original Article:** <http://www.mayoclinic.com/health/coronary-bypass-surgery/MY00087>

---

### Definition

Coronary bypass surgery is a procedure that restores blood flow to your heart muscle by diverting the flow of blood around a section of a blocked artery in your heart. Coronary bypass surgery uses a healthy blood vessel taken from your leg, arm, chest or abdomen and connects it to the other arteries in your heart so that blood is bypassed around the diseased or blocked area. After a coronary bypass surgery, normal blood flow is restored. Coronary bypass surgery is just one option to treat heart disease.

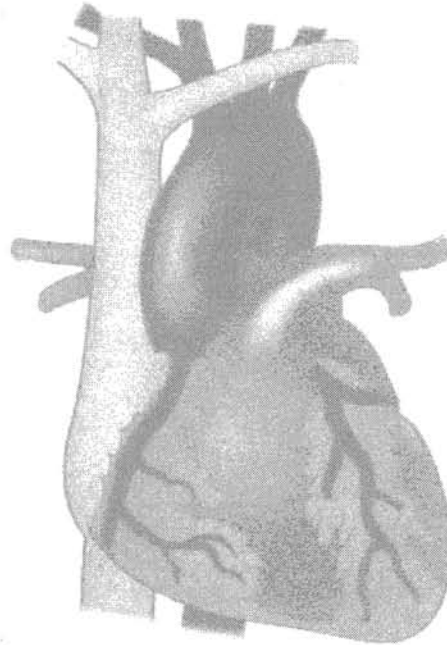
Coronary bypass surgery can help reduce your risk of having a heart attack. For many people who have coronary bypass surgery, symptoms such as chest pain and shortness of breath are reduced after having the surgery.

## Coronary bypass

Select a button to view the process of a coronary bypass



Normal Heart - Please click on the buttons above to view the different stages of a coronary bypass.



© Mayo Foundation for Medical Education and Research. All rights reserved.

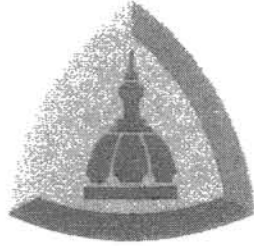

## Why it's done

You and your doctor can consider whether coronary bypass surgery or another artery-opening procedure, such as angioplasty or stenting, is right for you.

### Coronary bypass surgery is an option if:

- You have severe chest pain caused by narrowing of several of the arteries that supply your heart muscle, leaving the muscle short of blood during even light exercise or at rest. Sometimes angioplasty and stenting will help, but for some types of blockages, coronary bypass surgery may be the best option.
- You have more than one diseased coronary artery and the heart's main pump — the left ventricle — is not functioning well.
- Your left main coronary artery is severely narrowed or blocked. This artery supplies most of the blood to the left ventricle.

THE JOHNS HOPKINS WHITE PAPERS



JOHNS HOPKINS  
M E D I C I N E

2 0 0 6

JOHNS HOPKINS MEDICINE  
BALTIMORE, MARYLAND

### Bypass Surgery vs. Angioplasty

Angioplasty has several advantages over bypass surgery. Angioplasty is a relatively simple procedure, there is no need for general anesthesia, and the risks of open heart surgery are avoided. In addition, after only a 1-night stay in the hospital, patients can resume their normal activities almost immediately. Angioplasty is also less expensive than bypass surgery.

As described earlier, restenosis is a possibility with angioplasty, and patients who undergo this procedure must accept the risk that a repeat angioplasty or, ultimately, bypass surgery may become necessary. In comparison, bypass surgery may keep coronary arteries open longer and may produce better blood flow through these arteries. Bypass surgery generally provides good relief of angina for at least 5 years. Bypass surgery is usually favored over angioplasty for people with 1 or more of the following:

- **Narrowing of the left main coronary artery.** This vessel is the main artery supplying blood to the heart. Even a brief period of blockage of blood flow through this artery could damage the heart muscle and be fatal.
- **Narrowing of several vessels.** Bypass surgery is a better option than angioplasty when the buildup of plaque has caused multiple obstructions in an artery or has narrowed several arteries. This is because angioplasty is a more complex procedure to perform when the affected area is large and requires the implantation of several stents.
- **Narrowing at an arterial branch.** An arterial branch is where 1 artery meets another. Because angioplasty to remove plaque at this site may shift the plaque into an adjacent artery, causing a new blockage, bypass surgery is sometimes preferred.
- **Diabetes.** In a study conducted in the mid-1990s—the Bypass Angioplasty Revascularization Investigation (BARI)—the 7-year survival for people with diabetes was significantly better in those who underwent bypass surgery (76%) than in those undergoing angioplasty (56%). A more recent study (published in 2001) confirmed the advantage of bypass surgery over angioplasty in people with diabetes, with increased survival in the bypass group. However, these studies were conducted before drug-eluting stents were available, and the results may be different in future studies using such stents.

Among the drawbacks of bypass surgery are longer hospital stays and longer rehabilitation time than with angioplasty. In addition, a recent study of 261 bypass surgery patients found that about 40%

### NEW FINDING

#### Aspirin Before Surgery: Okay or Not Okay?

If a trip to the hospital operating room for coronary bypass surgery is in your future, and you're looking for ways to improve the outcome, taking aspirin beforehand may be a strategy worth pursuing. That was the take-home message from a study conducted at the Mayo Clinic.

The study involved 1,636 patients who underwent bypass surgery. About 80% of them had taken aspirin within 5 days of their operation, while the remaining 20% had not.

In the immediate post-surgery period, those taking aspirin pre-operatively were less likely to die in the hospital. While the in-hospital death rate was 1.7% among aspirin users, it climbed to 4.4% in the non-aspirin group.

Most doctors tell their patients to stop taking aspirin before surgery because its effects on blood platelets could increase the likelihood of internal bleeding. But the aspirin-takers in the study showed neither a greater chance of significant bleeding nor an increased need for blood transfusions.

These findings suggest that you may not need to stop taking aspirin in the days leading up to bypass surgery, and if you're not already taking aspirin you may want to start just before the procedure. But until further research confirms this finding, follow your doctor's advice on the use of aspirin before bypass surgery.

CIRCULATION

Volume 112, page 1286

August 5, 2005



had a decline in their mental abilities that persisted 5 years after surgery. (It's possible, however, that this decline was caused by underlying vascular disease and not the surgery itself.)

Except in an emergency situation, you have time to get a second opinion when deciding between angioplasty and bypass surgery. Getting that second opinion will help you feel more confident that you've made the right decision. For advice on finding a second opinion, see the feature on pages 54–55.

### **Other Procedures To Improve Blood Supply to the Heart**

Besides bypass surgery and angioplasty, other newer procedures such as atherectomy, laser ablation, and enhanced external counterpulsation (EECP) are used in certain circumstances to improve blood flow through the coronary arteries.

**Atherectomy.** This procedure removes plaque from the inside of arteries. It involves the use of a high-speed rotary blade or drill to shave away portions of plaque that are narrowing a coronary artery. Using a catheter, the blade or drill is delivered to the site of the blockage. Atherectomy works best on large, straight arteries. The blade is usually used when the plaque is limited to 1 side of the artery wall; the drill typically produces better results than angioplasty for very long obstructions.

An atherectomy is often done prior to balloon angioplasty to remove some of the plaque; angioplasty then follows to compress or crush the remaining plaque against the walls of the arteries. Serious complications are rare, but may include unexpected vessel closure or a heart attack.

**Laser ablation.** This procedure is similar to angioplasty, but instead of a balloon at the tip of the catheter there is a probe. The probe is heated with a beam of laser light that cuts through the plaque and virtually burns it away. However, there are potential complications associated with laser ablation—most notably, accidentally making a hole in the artery wall. The procedure may one day prove useful in reopening completely blocked arteries, as well as in destroying plaques that cannot be treated with angioplasty, either because the plaques are too long or are too hardened by calcium deposits. At present, the procedure is rarely used.

**Enhanced external counterpulsation.** Some people with angina do not get sufficient pain relief from medication or angioplasty, and can't undergo bypass surgery because of poor health. For these individuals, a noninvasive procedure called enhanced external counterpulsation (EECP) may improve angina symptoms and quality of life.

## MORE PATIENTS ARE HAVING LESS INVASIVE BYPASS SURGERY

For people who need coronary artery bypass surgery, the chance of having a minimally invasive procedure rather than an open-chest operation is increasing. Advances in techniques and instrumentation are making the less intrusive operation a possibility for many more patients, regardless of age, gender, extent of disease and whether they have had prior bypass surgery.

Minimally invasive cardiac surgery (MICS) eliminates the most traumatic and painful aspect of conventional coronary artery bypass surgery (CABG, pronounced "cabbage"): the need for a median sternotomy, in which doctors split apart the breastbone and spread open the rib cage to reach the heart. Minimally invasive surgery usually means a shorter recovery, less pain and a quicker return to normal activities than with CABG.

MICS, which represents one of the biggest changes in heart surgery since the introduction of CABG 35 years ago, refers primarily to two different procedures: minimally invasive direct coronary artery bypass (MIDCAB) and port-access coronary artery bypass.

Until recently, MICS was available only to patients with one or maybe two blocked arteries. Patients requiring triple or quadruple bypass usually had a conventional procedure. All that is changing. "The technology and equipment are evolving very rapidly," says Cleveland Clinic cardiothoracic surgeon Joseph Sabik, M.D.

### MIDCAB

MIDCAB is most suited for men and women who have single-vessel disease in an artery located on the front side of the heart, either the left anterior descending artery or the right coronary artery. The surgery is performed on a beating heart, and as a result does not require the use of a heart-lung machine. It is therefore a good option for patients with peripheral vascular disease, who are at increased risk during cardiopulmonary bypass with the heart-lung machine.

The surgeon makes a small incision in the left side of the chest between the ribs to expose the heart, as well as the internal mammary (chest) artery that will be used to bypass the blockage. The area of the heart to be operated on is stabilized to make the procedure easier to perform. (Bypassing an artery on a beating heart has been likened to trying to stitch together two moving pieces of well-cooked, thin spaghetti.)

One stabilizer, called the Octopus, uses suction cups to lift and stabilize the area of the heart around

the artery to be grafted. Another stabilizing system uses a device that looks like a two-tined fork, which immobilizes the area by applying pressure to the heart muscle on either side of the artery.

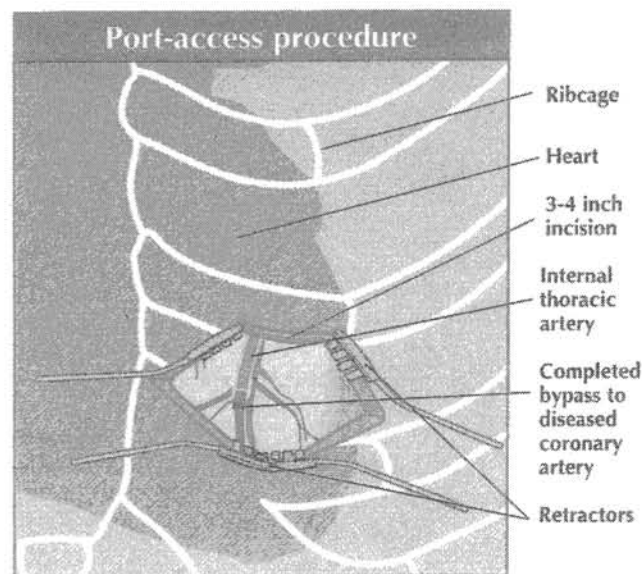
When the area is stable, the surgeon connects the mammary artery to the blocked artery, completing the bypass. The procedure generally takes about two hours.

Although it is too soon to evaluate long-term results, early studies of patients undergoing MIDCAB — including high-risk patients — report clinical outcomes comparable to standard CABG. Because the heart-lung machine is not used, MIDCAB avoids the risks associated with it, including the possibility of impaired cognitive function. Some physicians believe it is the use of the heart-lung machine that accounts for the 6% or so of bypass patients who are left with neurological damage.

### Port-access

Patients requiring multivessel bypasses or second bypasses (which doctors call reoperations) may be candidates for the port-access procedure, a technique that allows surgeons to operate through a small, three-to-four-inch incision in the chest. As with conventional CABG, the heart is stopped and protected with special drugs. But a different method is used to connect the heart to the heart-lung machine.

Rather than hooking up the heart directly to the bypass machine, the surgeon performing port-access will insert thin, flexible tubes (cannulas) into blood vessels in the thigh (femoral artery) and neck and





thread them to the heart. The tubes are then used to connect the patient to the heart-lung machine.

Once the patient's pumping activity is taken over by the heart-lung machine, the surgeon performs the bypasses through the small incision. Because the heart is "at rest" and filled with blood, the surgeon can operate on the front, side and back of the heart by lifting and turning the heart as necessary to get access to the blocked arteries. In women, port-access incisions are usually made beneath the breast to conceal the resulting scar.

One advantage to port-access is a decreased risk of developing atrial fibrillation, an irregular heart rhythm that occurs in approximately 25–30% of patients following conventional bypass surgery. "Although medication is effective in restoring normal rhythm to the heart, atrial fibrillation does increase the risk of stroke," Dr. Sabik notes. "So any decrease in this risk is a plus."

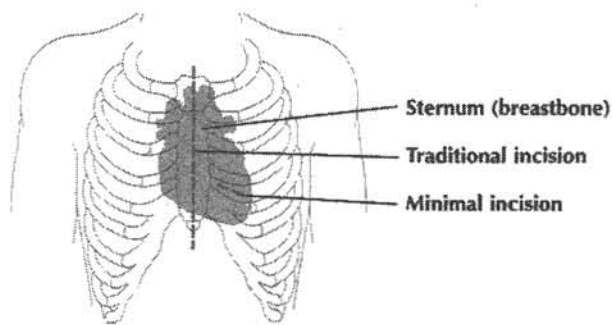
Approximately 20% of Dr. Sabik's patients requiring multivessel bypasses or reoperations have undergone port-access.

Early in 1998, the first report from the Port-Access International Registry (PAIR) study, which included data from more than 1,000 patients at 121 medical centers, revealed that the procedure is safe, with a low incidence of complications, equivalent to standard open-chest surgery. Further research is being done to measure long-term efficacy, recovery time and the impact of the procedure on a patient's quality of life.

Of course, port-access and MIDCAB procedures are still serious surgery. Both techniques are being carefully monitored by the American Heart Association, the American College of Cardiology and the American College of Surgeons, whose positions reflect cautious optimism until more data on the procedures' effectiveness are obtained and analyzed. No one yet knows whether the long-term results will prove to be as good as those with conventional open-chest coronary artery bypass surgery.

### What are the benefits?

Patients undergoing minimally invasive bypass surgery experience reduced trauma and less pain during the recovery period. "Postoperative pain can be one of the hardest things for patients to deal with following conventional bypass surgery," says Dr. Sabik. After traditional open-chest surgery, patients may experience difficulty breathing because of the pain associated with the sternotomy. (This can be aggravated if the patient is a smoker.) MICS procedures also eliminate the need for a ventilator (breathing tube) during recovery, and seem to reduce the risk of other complications associated with CABG. The percentage of patients who have to contend with postsurgical infections is far lower when MICS is done.



The smaller incisions also reduce the risks of other postoperative complications such as bleeding. "Overall, patients go home sooner and enjoy a more rapid recovery," notes Dr. Sabik.

At The Cleveland Clinic, patients typically stay in intensive care 24 hours or less. Their hospital stay is often reduced to three or four days, compared to five to seven days following conventional surgery. Postoperative recovery may be two to four weeks, compared to six to eight weeks with traditional open-heart surgery.

Older patients with other health problems may require a longer hospital stay after a minimally invasive procedure than younger patients, but nonetheless it will probably be shorter than it would have been after conventional bypass surgery. "We originally believed these techniques would be most appropriate for younger, relatively healthier patients," Dr. Sabik says. "However, experience has taught us that the opposite is often true. With port-access or other minimal techniques, the physical toll on the body is less, which may actually make it a better choice for some older patients."

### Who is a candidate?

There are no hard and fast rules when deciding who can have minimally invasive bypass surgery. "We tailor the procedure to the patient, not the other way around," says Dr. Sabik. For example, an 80-year-old patient who requires a reoperation may be a good candidate because of the location of his blockages, and because he is otherwise in good health. Conversely, a younger patient may not be a candidate because of obesity or an enlarged heart. Minimally invasive techniques are equally suitable for men and women.

If you are facing coronary bypass surgery, your surgeon will make a recommendation based on how best to treat your particular blockages with the least risk to you. In many patients, that may dictate a conventional procedure. If your surgeon is more comfortable performing the conventional procedure, you may be better off sticking with the tried-and-true method. Currently, only a small percent of open-heart surgeries are performed using MICS procedures. But as technology continues to evolve and improve, that number is likely to keep growing. ■■

E

HONORABLE JUDGE RICHARD EADIE

1  
2  
3  
4  
5  
6  
7  
8  
9  
10  
11  
12  
13  
14  
15  
16  
17  
18  
19  
20  
21  
22

IN THE SUPERIOR COURT OF THE STATE OF WASHINGTON FOR KING COUNTY

LEONARDO C. MARIANO, pro se,

Plaintiff,

v.

SWEDISH CARDIAC SURGERY,

Defendants.

NO. 11-2-15733-4 SEA

DEFENDANT SWEDISH CARDIAC SURGERY'S[sic] ANSWERS TO PLAINTIFF'S FIRST SET OF FOUR INTERROGATORIES TO DEFENDANT

**DEFENDANT'S ANSWERS AND OBJECTIONS**  
**TO PLAINTIFF'S INTERROGATORIES**

**GENERAL OBJECTION**

Defendant Swedish Cardiac Surgery [sic] objects to these interrogatories to the extent it is clear that plaintiff has not obtained expert review and does not have the required expert testimony to continue to pursue his ongoing claim. RCW Ch. 7.70, *et. seq.* It is further clear that without competent, qualified expert input, plaintiff is not able to properly interpret or comprehend the medical records in his possession. Based on plaintiff's medical chart, it is clear that he had cardiovascular disease in his right and left coronary arteries.

Plaintiff's Right Coronary Artery was found to be "heavily calcified throughout its coursing" with an 85-90% stenosis beyond the acute marginal. Proximally, that artery had about an 80% stenosis within the first 2 cm of its coursing. See attached March 30, 2006 Procedure Report on Selective Coronary Arteriogram.

Plaintiff's Left Anterior Descending Coronary Artery had a 50-60% narrowing right at its origin. In the midsection of the left anterior descending artery, there was a section that was "almost aneurysmal" followed by an 85-90% midsection stenosis. The diagonal system, specifically the

DEFENDANT SWEDISH CARDIAC SURGERY'S[sic]  
ANSWERS TO PLAINTIFF'S FIRST SET OF FOUR  
INTERROGATORIES TO DEFENDANT - 1

**Andrews • Skinner, P.S.**  
645 Elliott Ave. W., Ste. 350  
Seattle, WA 98119  
Tel: 206-223-9248 • Fax: 206-623-9050

1 superior branch, had an 85-90% stenosis over about a 1.5-2 cm length. See attached March 30,  
2 2006 Procedure Report on Selective Coronary Arteriogram.

3 Without the appropriate and necessary coronary artery bypass grafting procedure performed on  
4 April 4, 2006, plaintiff was at significant risk for a cardiac event which would potentially have  
5 been fatal or rendered him significantly incapacitated.

6 **INTERROGATORY NO. 1:** In attached Exhibit K, Dr. David Gartman (Defendant's  
7 surgical doctor) stated: ". . . . *The patient was returned to the operating room later that evening for*  
8 *post-operative sternal bleed.*" Please elaborate in detail why and how Plaintiff had to undergo a  
9 post-operation.

10 **Answer:** As plaintiff's medical records reflect, plaintiff was returned to the operating room  
11 following his coronary artery bypass procedure on April 4, 2006, to address and control  
12 postoperative bleeding. Copies of the relevant records are attached.

13 **INTERROGATORY NO. 2:** In attached Exhibit J, Dr. David Gartman (Defendant's  
14 surgical doctor) stated: ". . . . *The PDA and distal **right** coronary artery were so hard throughout*  
15 *their length, there was nothing I could do with those.*" Does this not contradict the diagnosis of  
16 Defendant's Dr. John Peterson (in attached Exhibit I) who targeted the hardened **right** coronary  
17 artery as the culprit or reason why Plaintiff was suffering from chest pains and shortness of breath?

18 **Answer:** No. The quoted chart entry indicates that portions of plaintiff's right coronary  
19 artery were so damaged that they could not be salvaged or used in connection with the by-pass  
20 procedure to establish coronary revascularization. Defendant provided good and appropriate care  
21 for all of plaintiff's cardiac issues.

22 **INTERROGATORY NO. 3:** Referring to Interrogatory No. 2 above: Since Defendant  
did not do anything with the hardened right coronary artery, was it already harmless?

F-1

From: Beth Cooper <Beth.Cooper@andrews-skinner.com>  
To: Leonardo Mariano <mariano.leonardo@ymail.com>  
Cc: Pamela Andrews <Pamela.Andrews@andrews-skinner.com>; Liz Curtis <Liz.Curtis@andrews-skinner.com>  
Sent: Wednesday, October 12, 2011 9:50 AM  
Subject: RE: Mariano v. Swedish Cardiac Surgery, No. 11-2-15733-4 SEA

(A)

10/12/11

a)

Mr. Mariano,

I will change the date of my motion. The judge is available on January 13, 2012 at 10:00 a.m. Does that work with your schedule? Please let me know ASAP so I can reserve the date/time.

Also, to clarify, you are obligated to identify your trial witnesses to me DURING, not after discovery. In fact, the Court Rules (CR 11) together with the statutory requirements under RCW Ch. 7.70, compel you to have supporting testimony from a qualified medical expert witness PRIOR to filing a medical negligence lawsuit. If you in fact have an expert witness who supports your claims in this case, please identify that individual for me. I do understand if there is some specific information you still believe you will obtain through discovery, however, it is my understanding that you have all of your relevant medical records to provide to this witness. If my understanding is incorrect, please let me know immediately and I will provide the medical chart to you without the need for a separate discovery request.

Again, you must have a qualified medical expert supporting your claim to go forward with a medical negligence lawsuit. Please feel free to contact me with any questions.

Thank you for your attention to these matters.  
BETH COOPER

*Beth Cooper*  
Andrews • Skinner, P.S.  
645 Elliott Ave. W., Ste. 350  
Seattle, WA 98119  
Tel: 206-223-9248  
Email: [beth.cooper@andrews-skinner.com](mailto:beth.cooper@andrews-skinner.com)

F-2

**From:** Beth Cooper <[Beth.Cooper@andrews-skinner.com](mailto:Beth.Cooper@andrews-skinner.com)>  
**To:** Leonardo Mariano <[mariano.leonardo@ymail.com](mailto:mariano.leonardo@ymail.com)>  
**Cc:** Liz Curtis <[Liz.Curtis@andrews-skinner.com](mailto:Liz.Curtis@andrews-skinner.com)>  
**Sent:** Monday, November 28, 2011 8:53 AM  
**Subject:** RE: Mariano v. Swedish Cardiac Surgery, No. 11-2-15733-4 SEA

11/28/11

Mr. Mariano,

Email contact is perfectly fine, and I would be happy to speak with your attorney. Please provide me with his/her name, or provide him/her with my contact information. I will continue to contact you as a pro-se plaintiff until I hear from and/or receive a notice of appearance from an attorney on your behalf.

Further to your request, I will re-send the Swedish medical records under separate cover.

As I have previously explained, I will strike my motion for summary judgment if you provide the name of an expert witness who supports your claims in this lawsuit. I will want to schedule the deposition of any identified expert promptly. At this time, the motion will remain scheduled for January 13, 2012. ))

Thank you.  
BETH COOPER

*Beth Cooper*  
Andrews • Skinner, P.S.  
645 Elliott Ave. W., Ste. 350  
Seattle, WA 98119  
Tel: 206-223-9248  
Email: [beth.cooper@andrews-skinner.com](mailto:beth.cooper@andrews-skinner.com)



**Swedish Medical Center**

Unit	Name	MRN	Adm Date	Att Prov	DOB	Sex
F 3SW	Mariano, Leonardo C	1000706484	4/3/06	David M Gartman, MD	7/20/1931	M

**Procedures filed by N-A Conversion at 12/07/07 1630**

Author: N-A Conversion	Service: (none)	Author Type: (none)
Filed: 12/07/07 1630	Note 04/04/06 1258	
	Time:	

**PERIOPERATIVE TRANSESOPHAGEAL REPORT**

PATIENT: MARIANO, LEONARDO HOSPITAL NUMBER: 578729037  
 DATE OF BIRTH: 07/20/1931 DATE OF STUDY: 04/04/2006  
 AGE: 74Y VIDEO TAPE NUMBER:

INDICATIONS: Ventricular function and valvular assessment.

OPERATION: CABG x 4.

**PROBLEMS:**

1. Diabetes.
2. Hypertension.
3. Systolic murmur.

**PRE-CARDIOPULMONARY BYPASS FINDINGS:**

**PERICARDIUM:** The pericardium is normal. There is no effusion present.

**TRICUSPID VALVE:** There is mild central tricuspid regurgitation.

**RIGHT ATRIUM:** Right atrial size is normal.

**RIGHT VENTRICLE:** Right ventricular systolic function is normal. Right ventricular size is normal.

**PULMONIC VALVE:** Normal.

**INTERATRIAL SEPTUM:** There is no evidence of patent foramen ovale by color flow Doppler. Interatrial septum is intact.

**MITRAL VALVE:** Redundancy is seen in both leaflets, particularly at the tips of the anterior leaflets. The coaptation point is displaced superiorly, although no overt prolapse is noted.

There is a central and eccentric jet which is posteriorly directed. There is moderate mitral regurgitation. Inspection of the pulmonary veins shows systolic blunting.

**LEFT ATRIUM:** Left atrial size is normal. There are no masses present.

**LEFT VENTRICLE:** Left ventricular systolic function is normal, with an estimated ejection fraction of 60%. There is mild left ventricular hypertrophy, with a measured posterior wall thickness of 14 mm. Left ventricular chamber size is normal.

There are no regional wall motion abnormalities.

**INTERVENTRICULAR SEPTUM:**

**AORTIC VALVE:** The aortic valve is trileaflet. There is no significant stenosis or regurgitation. Leaflet cusps are mildly thickened.

**ASCENDING AORTA/AORTIC ARCH:** There is no significant atherosclerosis present. It is grade 1.

**DESCENDING AORTA:** There is mild atherosclerosis present, grade





2.

Preoperative Summary:

1. Preserved left ventricular systolic function, with an estimated ejection fraction of 60%.
2. No regional wall motion abnormalities.
3. Mild left ventricular hypertrophy (14 mm).
4. Moderate mitral regurgitation, with both central and eccentric components to the regurgitant jet. The eccentric jet is directed posteriorly. Redundancy is noted in both leaflets, particularly the tips of the anterior leaflet. The coaptation point of the mitral valve is displaced superiorly, although no overt prolapse is noted. Systolic blunting is seen in the pulmonary veins.
5. Mild tricuspid regurgitation.
6. No left atrial enlargement or right atrial enlargement.
7. Normal right ventricular function.

POST-CARDIOPULMONARY BYPASS FINDINGS:

PERICARDIUM: Unchanged.

TRICUSPID VALVE: Tricuspid regurgitation remains mild in severity.

RIGHT ATRIUM: Normal.

RIGHT VENTRICLE: Unchanged, with normal right ventricular function.

INTERATRIAL SEPTUM: Normal.

MITRAL VALVE: The mitral regurgitant jet is now severe. Both the central and the eccentric components are larger than preoperative examination.

LEFT ATRIUM: Normal.

LEFT VENTRICLE: Left ventricle is hyperdynamic, with an estimated ejection fraction of 70%. No regional wall motion abnormalities.

AORTIC VALVE: Unchanged.

ASCENDING AORTA/AORTIC ARCH/DESCENDING AORTA: Unchanged.

Postoperative Summary:

1. Hyperdynamic left ventricle, with an estimated ejection fraction of 70%.
2. No regional wall motion abnormalities.
3. Mitral regurgitation, now severe. Both central and eccentric jets are significantly larger than preoperative examination. Severity is confirmed through analysis of PISA, vena contracta and flow in the pulmonary venous system.
4. Remainder of examination unchanged.

Preoperative findings were discussed with the patient's cardiologist, Dr. John Petersen, who requested that no intervention be performed on the mitral valve.

LORI B. HELLER, MD #

LBH:04/04/2006 12:58:39  
sdg:04/04/2006 13:43:07  
550817 600266

cc:DAVID M. GARTMAN, MD #  
JOHN L PETERSEN, MD #